SARCOIDOSIS

Casey Schreiber, DO

UCI-CHOC Pediatric Residency

BACKGROUND

- Multisystem systemic granulomatous disease of unknown etiology that commonly affects young adults
- Hilar adenopathy, pulmonary infiltration, ocular and cutaneous lesions
  - Most frequently involve lung, but any organ
  - Children 1-5y: triad skin, joint, eye involvement without typical lung disease

EPIDEMIOLOGY

- Relatively rare in pediatric population
  - Unknown true incidence and prevalence in childhood, small # cases reported
- Most children age 13-15
- No sex predominance in children
- African Americans > Caucasian in the US
- South eastern and south central US endemic for childhood sarcoidosis

ETIOLOGY

- Genetic predisposition
- Chronic inflammatory disease, characterized by exaggerated immune response to unknown antigen
- Hallmark: sarcoid granulomas
- Macrophages initiate, T cell proliferation and immunologic interactions→granuloma
  - Persistent antigenic stimulation maintains process
  - Granulomas either resolve or heal by fibrosis

CLINICAL FEATURES

- Can affect any organ
- Children: eyes, skin, spleen, liver, lungs, lymph nodes
  - Constitutional symptoms: fever, fatigue, malaise & weight loss
  - Can be asymptomatic, remain undiagnosed
- Children 2 distinct forms: older kids with similar presentation as adults
  - Young kids (<5): triad of rash, uveitis, arthritis
    - Hilar adenopathy rare
- Pulm: dry hacking cough, +/- dyspnea, chest pain
  - Bilateral hilar adenopathy most common radiographic finding
  - Restrictive lung disease

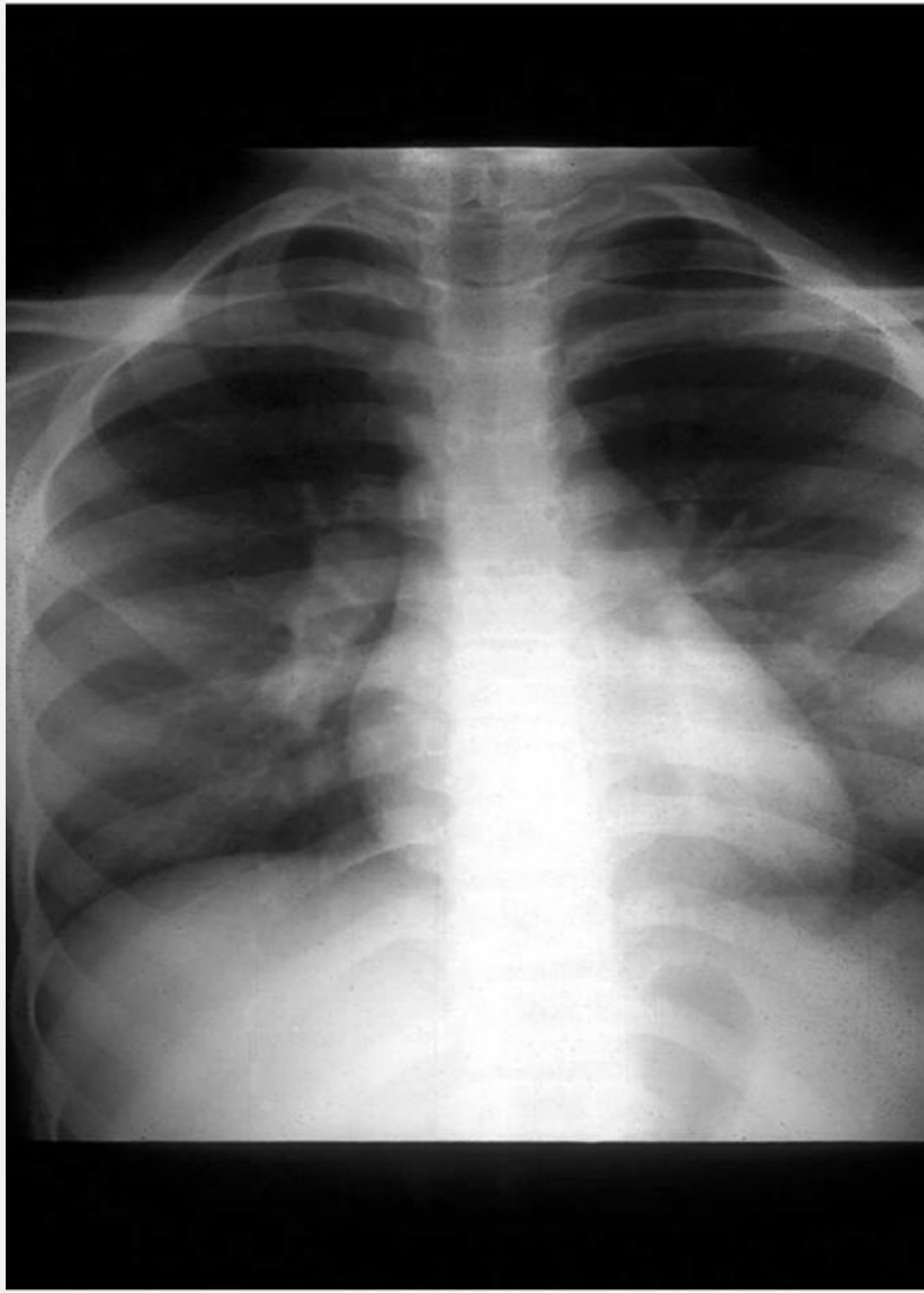

CLINICAL FEATURES CONT.

- Ocular: eye pain, blurriness, photophobia, redness
  - Anterior segment (uveitis or iritis) most common manifestation in children
  - Conjunctival granulomas 2nd most common
- Skin: erythematous rash common in children
  - soft, red to yellowish brown, or violaceous, flat-topped papules, found most frequently on the face
  - Large violaceous plaque like lesions
  - Erythema nodosum
- MSK: joint effusions, pain, rarely osseous involvement
  - Arthritis, multiple joints of upper and lower extremities
  - Bony and muscle involvement rare

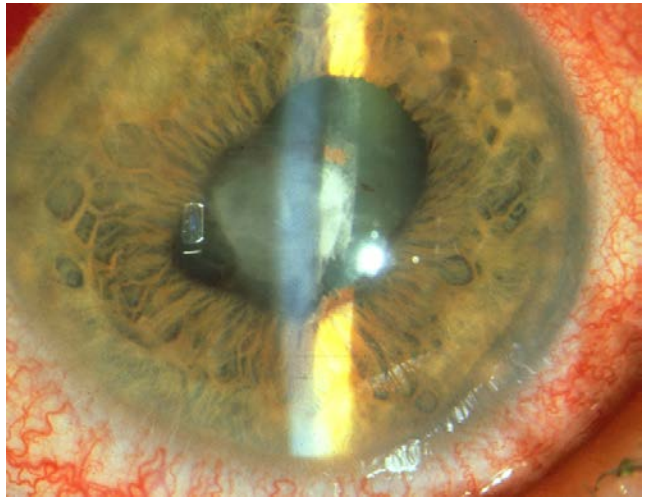

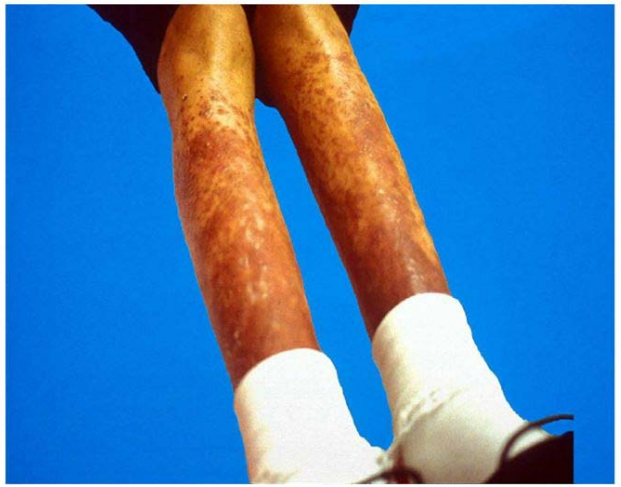

DIAGNOSIS

- Labs: may have elevated ESR, anemia, eosinophilia, leukopenia
- Hypergammaglobulinemia, impaired delayed hypersensitivity skin test
- Hypercalcemia and/or hypercalciuria
- Serum ACE elevated
- CXR
- Dx confirmed by non-caseating granuloma on biopsy
  - Must exclude infectious granulomatous conditions

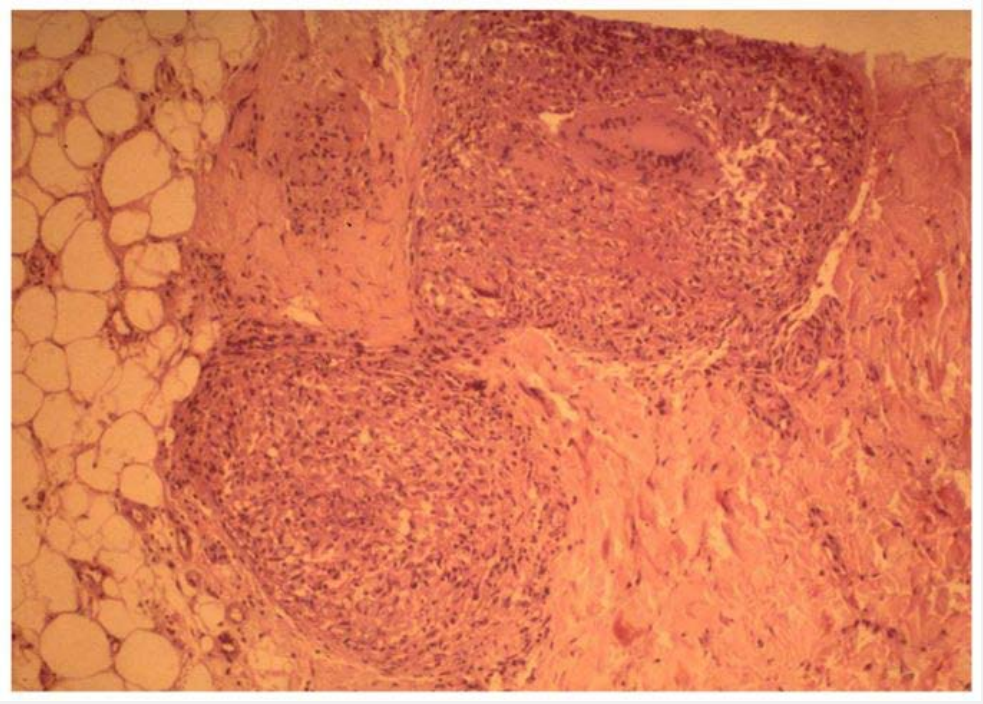

DIFFERENTIAL DIAGNOSIS

- Early onset sarcoidosis: mimic systemic JIA
- TB, histoplasmosis
- Lymphoma
- Hypercalcemia– primary hyperparathyroidism

TREATMENT

- Corticosteroids
  - Oral prednisone/prednisolone 1-2mg/kg/day for 4-8 weeks induction
  - Continued until clinical manifestations resolve/improve
  - Slowly taper to maintenance dose (6 mos)
- Asymptomatic patients may not need systemic therapy

PROGNOSIS

- Prognosis good compared to adults
- Spontaneous remission many
- Most children with considerable improvements on XR, PFTs
- Very young children with skin, arthritis, ocular triad have guarded prognosis
  - Likelihood of chronic progressive course
  - Progressive ocular disease→blindness

REFERENCES

- Shetty, A.K., Gedalia, A. Childhood sarcoidosis: A rare but fascinating disorder. *Pediatr Rheumatol* 6, 16 (2008). https://doi.org/10.1186/1546-0096-6-16
- Talmadge, E. K. Jr. Treatment of pulmonary sarcoidosis: Initial therapy with glucocorticoids. In: UpToDate, Post, TW (Ed), UpToDate, Waltham, MA, 2020.